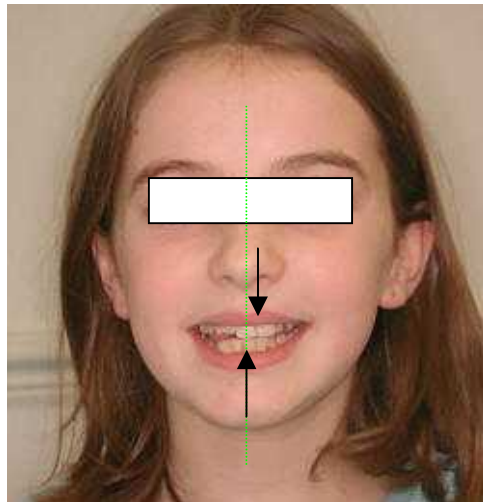
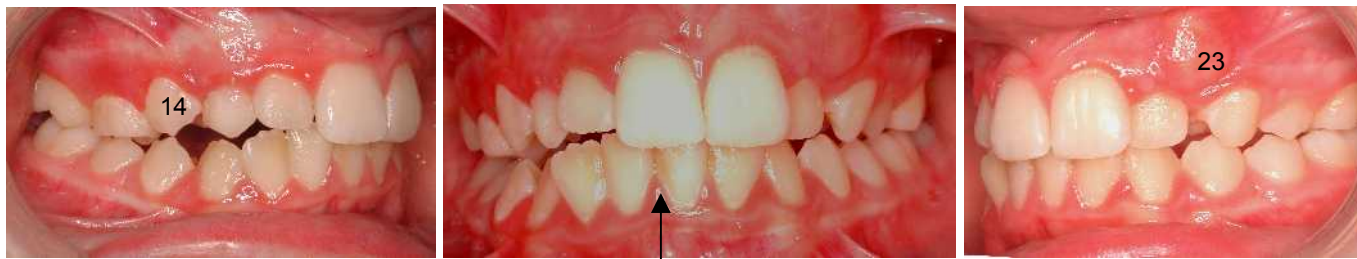




Dr Charles Daniels
BDS MScD PhD, FDSRCS (Eng)
MOrthRCS(Edin) FDSOrthRCS(Eng)
Specialist Orthodontist

Orthodontic treatment cases

Age adolescent. **Problem** Dental Centreline shift and impeded 23. **Treatment** : Asymmetric extractions and fixed appliances to close space.
Treatment took approximately 18 months and required extraction of tooth 14



Start



End