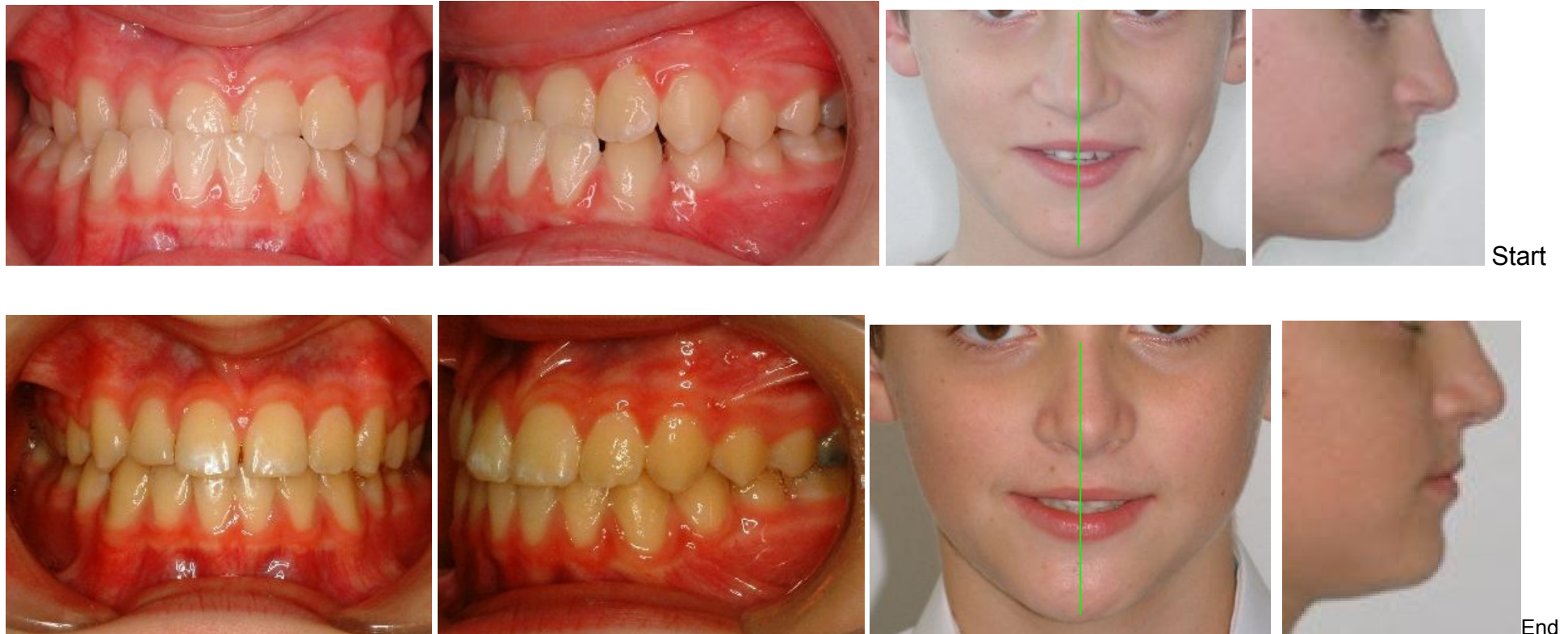


**Dr Charles Daniels**  
**Specialist Orthodontist**

**Orthodontic treatment cases** North Sydney Orthodontics

**Age** Adolescent **Problems** facial asymmetry associated with a dental crossbite. The chin point is slightly to the right of the facial midline and the lower dental midline to the right of the upper dental midline. The dental arches are quite well aligned so the dental position reflects the underlying mild excess and asymmetry of the lower jaw.

**Treatment** Fixed braces to upper and lower teeth completed the treatment in 18 months without dental extractions.



The commercial use of this material is strictly prohibited. Educational use is by permission only © North Sydney Orthodontics 2008